

False Positive Uptake of I-131 during a I-131 Whole Body Follow up scan in a patient with Differentiated Thyroid Cancer and Chronic Inflammation of Parotid Gland

Sioka C¹, Tsiouris S¹, Al-Bokharhli J¹, Vasiliou², Fotopoulos A¹

Department of Nuclear Medicine¹ and Department of Endocrinology², University Hospital of Ioannina, Ioannina, Greece

Abstract

Unusual high uptake of I-131 was detected in a parotid gland during a routine I-131 whole body scan in a patient of papillary carcinoma thyroid, raising the suspicion of functioning metastasis from the primary lesion in the thyroid. A review of the clinical history and additional scintigraphic evaluation revealed this to be of inflammatory origin.

Key words: Thyroid cancer, I-131 Scintigraphy, Parotid gland, Tc-99m sialoscintigraphy

World J Nucl Med 2007;6:120-121

Introduction

Thyroid tumors are the most common endocrine neoplasms. Most of these tumors are benign hyperplastic or colloid nodules or benign follicular adenomas. However 5 to 10% of the lesions that come to medical attention are carcinomas. There are three main histologic types of thyroid cancer: Differentiated, medullary and anaplastic. Differentiated lesions are again broadly divided into Papillary, Follicular and Hurthle Cell carcinomas. Patients with thyroid cancer will benefit from early detection and treatment, as early detection and appropriate therapy would lead to a cure or prolongation of life (1). I-131 whole body scan forms one of the most important aspects in the diagnostic work of patients of differentiated thyroid cancer, especially in the follow up and monitoring of these patients for detection of metastatic disease. However, false positive radioiodine whole body scans may occur due to unrelated pathology requiring further evaluation (2).

Correspondence

Dr. Chrissa Sioka MD
10, Patriarhou N Evangelidou
Ioannina, 454 44 Greece
E-mail; csiok@yahoo.com

Case Report

A 51 year-old woman with Papillary thyroid cancer was treated with 100 mCi of I-131 about four months after total Thyroidectomy. Patient reported for a regular check up after one year of radioiodine therapy. A follow up diagnostic whole body scan performed at 72 hrs after administration of 5 mCi I-131 revealed increased focal uptake of I-131 in right parotid gland. Persistence of I-131 uptake was also noted in the whole body scan performed after 5 days (Figure 1).

The patient was subjected to a sialo-scintigraphy with Tc-99m Perchnetate. Planar images of the anterior face was obtained at 30 minutes following intravenous injection of 5 mCi of Tc-99m Perchnetate. The images revealed uptake of Tc-99m perchnetate in the bilateral parotid glands, the left gland showing slightly more uptake compared to the right (Figure 2A). Subsequently the patient was given 6 ml of lemon juice orally to activate salivary secretion. Repeat planar images of the salivary glands were obtained in the anterior projection after 10 minutes of intervention with lemon juice. The post lemon juice images of the parotid glands revealed significant washout of radiotracer from the left parotid gland, while the right parotid showed poor washout, suggesting chronic parotitis (Figure 2B). Further detailed medical history revealed that the patient had a two-month history of tender swelling in the lateral aspect of her right jaw with pain during mastication; for which she received a two week course of broad spectrum antibiotics prescribed by a local physician with good results.

Discussion

I-131 Whole Body Scan plays a very important role in the follow up and management of patients with well-differentiated thyroid cancer. A number of cases of false positive studies have been reported, such as effusions, second primaries and delayed excretion by usual physiological routes. Since radio-iodinated thyroid hormones are secreted through the entero-hepatic cycle, diffuse uptake in the stomach is possible (2,3). Iodine is also normally taken up by the salivary glands and this normally shows up on the whole body scan as normal physiological

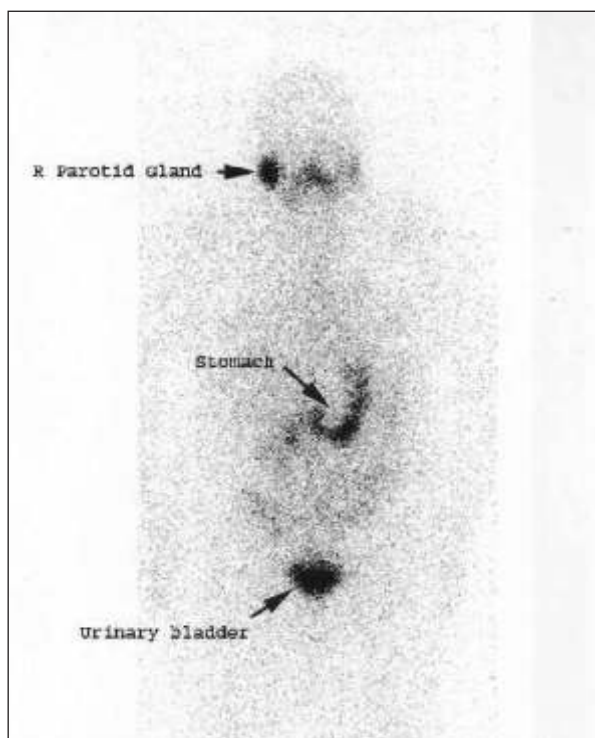


Figure 1. I-131 whole body scan. Anterior view I-131 whole body scan performed at 5 days after oral administration of 5 mCi of I-131. The scan shows intense and persistence of I-131 in the right parotid gland.

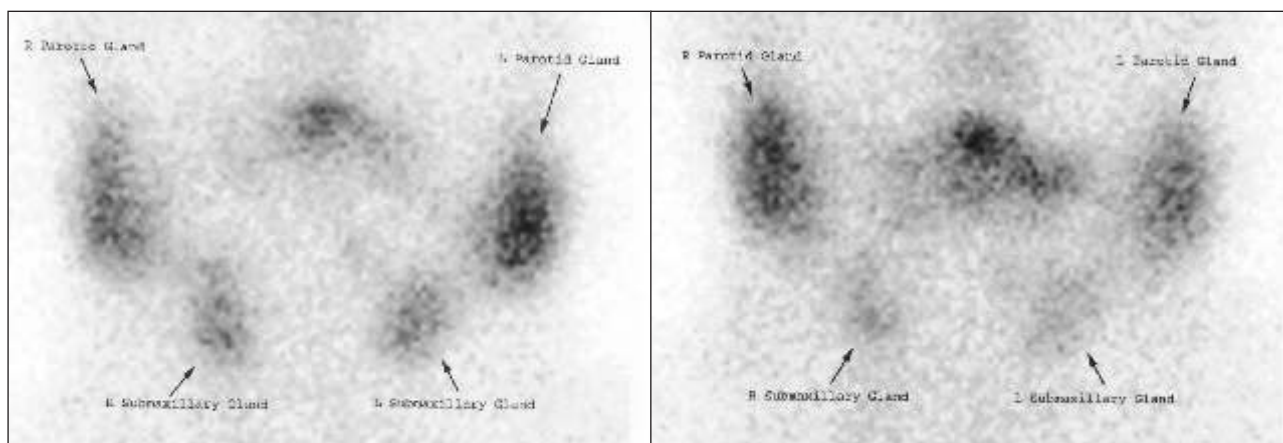


Figure 2. Tc-99m Pertechnetate sialoscintigraphy performed before (A) and after (B) oral administration of lemon juice. Study shows poor washout of radiotracer from right parotid gland following oral administration of lemon juice.

metabolism of I-131. However, the persistence of I-131 with a rising trend on delayed scans raised the suspicion of metastasis versus non-specific focal uptake. Chronic parotitis or sialadenitis may accumulate I-131 and give false positive results mimicking functioning metastasis from thyroid cancer. A few papers have reported similar cases in the past (4). Additional investigations such as sialoscintigraphy may be necessary to establish the correct diagnosis.

References

1. Little JW. Thyroid disorders. Part III: Neoplastic Thyroid Disease. *Oral Surg Oral Med Oral Pathol Oral Radiol Endod.* 2006; 102: 275-80.
2. McDougall IR. Whole Body Scintigraphy with radioiodine-131. A comprehensive list of false-positives with some examples. *Clin Nucl Med* 1995; 20: 869-75
3. Schneider JA, Divgi CR, Scott AM, et al. Hiatal hernia on whole body radioiodine survey mimicking metastatic thyroid cancer. *Clin Nucl Med* 1993; 18: 751-3
4. Kim S, Park CH, Yoon SN, Hwang K. A false-positive I-131 whole body scan in chronic parotitis: A case Report. *Clin Nucl Med* 2001; 26:236-7